

Blepharokeratoconjunctivitis in Kids: How and why I Treat Them Differently



Nicholas Colatrella, OD, FAAO, Diplomate AAO, ABO, ABCMO

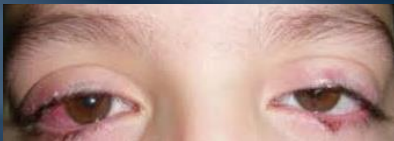

Disclosures

- Allergan Pharmaceuticals Speaker's Bureau
- Shire Pharmaceuticals
- Bio-Tissue
- BioDLogics, LLC
- Katena/ODP
- Seed Biotech
- Johnson and Johnson Vision Care, Inc.

Introduction

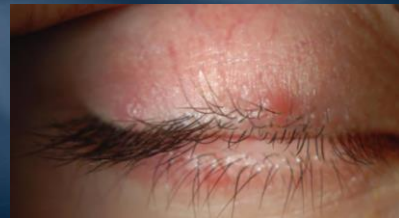- Blepharokeratoconjunctivitis (BKC) is an important and underdiagnosed chronic inflammatory disorder in children that may lead to visual loss
 - Commonly misdiagnosed and treated incompletely



Blepharokeratoconjunctivitis, Chronic pediatric ocular rosacea, Blepharokeratitis, Chronic phlyctenular keratoconjunctivitis, Phlyctenular blepharokeratoconjunctivitis, and Meibomitis-related keratoconjunctivitis

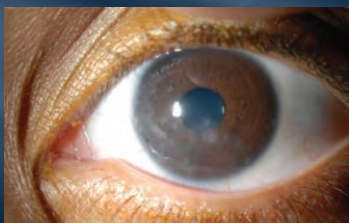
Introduction

- This disorder describes a spectrum of clinical manifestations, ranging from chronic eyelid inflammation and recurrent chalazia to conjunctival and corneal inflammation



Introduction

- The corneal inflammation may lead to neovascularization, scarring, and, in extreme cases, perforation
 - Early detection and aggressive, long-term Tx both in office and at home with patient / parent education is paramount



Introduction

- BKC in children can cause significant symptoms including irritation, watering, photophobia and loss of vision from corneal opacity, refractive error or amblyopia
- Treatment of BKC is directed towards modification of meibomian gland disease and the bacterial flora of lid margin and conjunctiva, and control of ocular surface inflammation
- The management must be multidisciplinary, including dermatologists, optometrists, ophthalmologists and pediatricians

Incidence

- BKC may present from 6 months to teenage years, but most commonly has onset at 4–5 years of age
- Hammersmith found the mean age of onset was 4.1 years, but the mean age at referral was 6.6 years
 - BKC with their most common pediatric diagnosis over 6 yr period
- Jones et al found the mean age of onset of 4.5 years and referral at 6.9 years.
- The age of onset preceding the age of appropriate diagnosis and therapy by several years has been observed in multiple studies
- In most adult cases, ocular manifestations of rosacea are preceded by cutaneous signs, making the diagnosis easier
 - In BKC the ocular involvement may precede dermatologic manifestations in more than half of the patients, delaying the diagnosis

Incidence

- Fair-skinned children of European descent are more commonly affected, although any ethnic group is susceptible
- 259 patients of 13 studies, 162 are girls (62.5%) and 97 are boys (37.5%), the opposite of what was found by Gupta et al 615 patient study
- A positive family history for rosacea was found in nine of the 34 patients of two series (26.5%)
 - Since children with rosacea are more likely to have familial rosacea, it is important to obtain family history data, which can help suggest the diagnosis

Incidence

- By time more severe cases are referred and Tx, many have already lost vision due to induced astigmatism and corneal scarring
- When appropriately diagnosed and treated, the inflammatory sequelae can often be controlled and vision maintained
- When misdiagnosed or improperly treated, children may develop vision threatening corneal changes, compounded by the fact that they are in the amblyogenic age range
- Pediatricians should be educated about cases of chronic recurrent “Pink Eye” and need for referral

Etiology

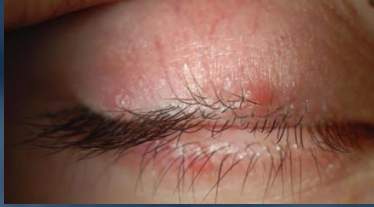- Exact mechanism of BKC remains unknown
 - Probably different regulatory systems involved
 - The infection by microbial organisms may have an important role
- Demodex folliculorum, possibly represents a contributing cofactor to the inflammatory reaction
 - bacterium Bacillus oleronius has been isolated from Demodex folliculorum mites and found to be responsible to trigger an immune system response
- Gastric coinfection with Helicobacter pylori has also been implicated, since this bacteria has the ability to produce flush-inducing toxins
- Staphylococcus aureus and Staphylococcus epidermidis are common organisms but their relationship with BKC is questionable

Etiology

- Bacterial lipases and interleukin-1 alpha and elevated concentrations of matrix metalloproteinases are responsible for the inferior corneal stromal thinning
- Rosacea induces vasodilation with increased blood flow and vessel permeability leading to erythema, telangiectasias and lymphedema of the affected tissues, especially in the eyelids
- The histopathological changes are unspecific, showing perifollicular infiltrates consisting of lymphohistiocytes, epithelioid and giant cells

Clinical Manifestations

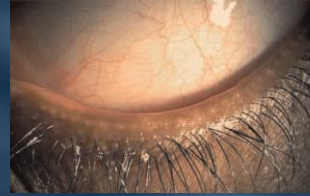- Patients and parents most commonly present with concerns of:
 - Pain
 - Redness
 - Burning
 - Itching
 - Tearing
 - Foreign body sensation
 - Photophobia
- By definition, all patient with BKC have lid disease. One of the early signs is often recurrent chalazia, which should alert the optometrist, ophthalmologist or pediatrician to the possibility of BKC
- In 12 studies, including 245 patients, 185 (75.5%) had bilateral involvement, generally asymmetrical. In Gupta et al, only 47.5% had bilateral involvement



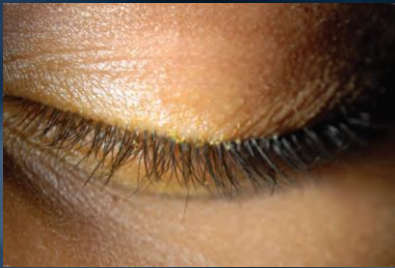- Six-year-old female with multiple chalazia and telangiectasia along lid margins (Picture from Hammersmith, KM)
- Eyelid involvement may precede the other features in months to years, because it is primarily an eyelid margin inflammation, such as blepharitis or meibomitis. Corneal and conjunctival are secondarily involved

Clinical Manifestations

- There is often both chronic anterior and posterior blepharitis
- Anterior eyelid inflammation (seen less often) includes:
 - Crusting / Flaking
 - Scaling
 - Collarette formation



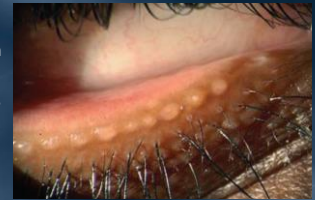
Anterior blepharitis: visible flaking on eyelash margin (picture from Shtein)



- Nine-year-old African-American girl with history of multiple chalazia. Examination reveals anterior blepharitis (Picture from Hammersmith, KM)

Clinical Manifestations

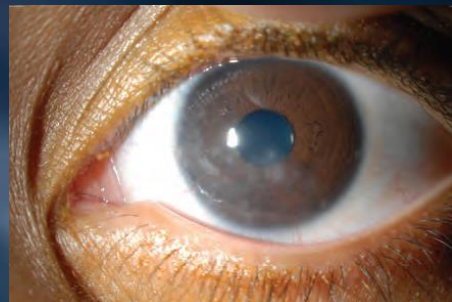- Posterior inflammation is present in some form in all cases and may include:
 - Meibomian gland pouting
 - Capping hypertrophy
 - Telangiectasia
 - Irregular eyelid margin
 - Chronic follicular conj
 - Periph Corneal Pannus
 - SEI's
 - Punctate keratopathy



Posterior blepharitis: inspissated meibomian gland openings (picture from Shtein)

Clinical Manifestations

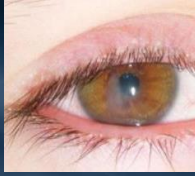- Conjunctival hyperemia is common
- Corneal inflammation is common and tends to present later than lid inflammation
 - Superficial punctate keratitis is often seen
 - Peripheral ulcerations or classic phlyctenules
 - Corneal scarring is often inferior and peripheral but may be extensive and central in severe cases
 - Corneal perforation is rare but may occur



- Corneal scarring with inferior vascularization (Picture from Hammersmith, KM)

Clinical Manifestations

- Visual acuity is often reduced at presentation.
- In an evaluation of 40 children
 - Jones et al found a median monocular best corrected visual acuity 20/40 (0.28 logMAR) at presentation
- Visual acuity is affected by:
 - Astigmatism, which results from corneal scarring and vascularization
- Doan et al found a mean astigmatism of 0.80 ± 0.89 diopters (range 0–3 diopters), all in patients with corneal scarring and vessels



Clinical Manifestations

- The hallmark cutaneous findings in kids with acne rosacea is facial erythema, telangiectasias, flushing, and papules and pustules restricted to the cheeks, chin, forehead, and nasolabial folds
- These findings may be present in 20–50% of patients with BKC
 - There is no correlation between the severity of BKC and inflammatory cutaneous rosacea
- Cutaneous involvement does not always develop before ocular manifestations
- The symptoms may also overlap with acne, especially during the teenage years, which can complicate the diagnosis

Area of involvement	Sequelae
Eyelid	Telangiectasias and erythema of the lid margin, meibomian gland dysfunction, anterior blepharitis, recurrent chalazia/hordeola, madarosis, trichiasis
Conjunctiva	Interpalpebral or diffuse hyperemia, papillary and/or follicular reaction, pinguecula, scarring
Cornea	Punctate erosions, pannus, superficial neovascularization, lipid deposition, spade-shaped infiltrate, scarring, thinning, ulceration, perforation, phlyctenule, Insufficiency of tear film with abnormal Schirmer test
Sclera	Episcleritis, scleritis
Uvea	Iritis (rare)

Differential Diagnosis

- BKC is most often misdiagnosed as herpes keratitis or allergic or viral conjunctivitis
- BKC can cause chronic follicular conjunctivitis with acute exacerbations that can be mistaken for viral and allergic conjunctivitis
 - Careful hx and SLE of eyelid margins can help distinguish
- The nature of viral conjunctivitis is quite different and the recurrent nature of BKC should help to distinguish
- Allergic conjunctivitis does not have the lid disease seen in BKC
- Once again, a history of recurrent chalazia is often present with BKC and should heighten suspicion

Differential Diagnosis

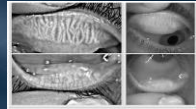
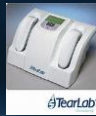- The most frequent misdiagnosis is herpes simplex virus (HSV) keratitis
- In BKC, the infiltrates are often where the lid margins cross the limbus (at 2, 4, 8, and 10 o'clock)
 - HSK infiltrates can be at any location
- Herpes simplex virus can mimic BKC, though it would more likely be unilateral, and lacking eyelid marginal changes
 - Even in cases of BKC with significant asymmetry, lid disease and mild corneal findings are often present in the less affected eye
 - When possible, checking corneal sensation is also helpful
 - Recurrent unilateral keratoconjunctivitis with decreased corneal sensation is highly suspicious for HSV not BKC

Differential Diagnosis

- Frequent chalazia with multiple recurrences can be caused by infestation with Demodex mites which can be found around the base of eyelashes, or within the meibomian glands
- Demodex folliculorum can cause anterior blepharitis and Demodex brevis has been implicated in recurrent chalazia, posterior blepharitis and chronic BKC
 - Liang's study highlights the prevalence of D. brevis in pediatric cases of recurrent chalazia, with microscopic evidence of demodicosis in 70.2% of the chalazia kids as compared with 13.3% of controls without chalazia
- Slit lamp evaluation may show cylindrical dandruff sleeves around the base of the lashes
- These studies highlight the need to suspect Demodex in pediatric cases of chronic BKC

Point of Care Testing

- Tear Film Osmolarity
- Meibography
- MMP-9
- TBUT vs Non-Invasive TBUT



Treatment

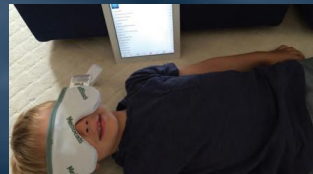
- It is important for families of children with BKC to understand that this is a chronic inflammatory condition with exacerbations and remissions
 - Treatment requires a minimum of three months' antibiotic therapy and a subsequent gradual tapering
 - Condition will wax and wane with a recurrence rate of 40%
- Patient and parent education, along with demonstration of techniques for eyelid compression and hygiene are paramount for success
- Treatment is targeted at opening the plugged up meibomian glands and clearing them of bacteria and oily debris

Treatment

- Therapy for BKC is generally approached in a stepwise fashion, beginning with essential lid therapy
- Patients are instructed to use warm compresses for 5 min, twice daily min (to melt glandular secretions)
 - This can be combined with bathing or when otherwise distracted with television or music
- Microwavable moist heat packs are a good option (both children and adults)
- After heat, vigorous massage of the lids just at the margin with firm pressure applied by the fingertip can allow expression of the glands
 - The role of the eyelid massage immediately after the heat packs cannot be overemphasized

Treatment

- Parents and patients should be instructed that the lid hygiene routine is to be maintained indefinitely because of the chronic nature of this disorder
- Its important to keep kids distracted during the process



Treatment

- Therapy directed toward anterior blepharitis includes dilute baby shampoo or commercially available foams and cleansers
 - Baby shampoo may actually damage goblet cells
 - Avenova approved for all age ranges
- A number of organisms found on the eyelid margins of adults with blepharitis are thought to contribute to the pathophysiology, including:
 - Staphylococcus aureus
 - Propionibacterium acnes
 - Yeasts
 - Fungi
 - Demodex

Treatment

- Studies have found therapeutic potential for tea tree oil shampoo which has broad antibacterial, antifungal and anti-Demodex properties
- The active ingredient in tea tree oil has been shown to eradicate the Demodex mites
- Cliradex eyelid hygiene wipes contain terpinen-4-ol, the most potent ingredient in tea tree oil, and are recommended for use twice a day for 6 weeks to cover two life cycles of the mites
- Studies of the use of tea tree oil for treatment of pediatric BKC were not found

Treatment

- The use of flax seed oil has been reported to aid in the maintenance therapy for lid inflammation
- There is little information in the literature to discuss appropriate dosing and long-term side-effects of flax seed oil in children
 - Jones et al. used 2.5 ml daily, reducing to alternate days for a maximum of 6 months
- Topical antibiotics with broad gram-positive coverage, particularly aimed at Staphylococcus and Streptococcus organisms, are also utilized.
 - nightly ointment with either bacitracin or erythromycin ophthalmic ointment

Treatment

- Topical lubricants are used to protect the surface given the tear dysfunction
 - Preservative-free lubricants are favored, especially when tear substitutes are indicated more than three to four times daily
- The lack of lipid in preventing tear film evaporation can make these children symptomatic with chronic dry eye symptoms
- Increased use of small screen devices may also lead to less frequent blinking and more breakdown of the ocular surface in children
- The rewetting drops should be used throughout the day, with instructions to the school nurse as well
- A room humidifier can be helpful in the area where the child studies or plays

Treatment

- Many severe cases of BKC require topical steroids to control the inflammatory corneal infiltrates and neovascularization
- Starting with milder drops such as loteprednol or fluoromethalone in children may be beneficial because of the difficulty in measuring their intraocular pressure
- Some children need a weak topical steroid just once or twice a week for a longer period to control the disease

Treatment

- Doan et al. reported use of topical azithromycin 1.5% eye drops in 19 children with BKC aged 4–16
- They reported that ocular inflammation was controlled by azithromycin in 15/19 patients
 - utilized a discontinuous treatment regimen
 - 3 consecutive days / 3 times for month one
 - 3 consecutive days / 2 times for month two
 - 3 consecutive days / 1 time for month three and beyond
 - Patients with sight-threatening corneal infiltrates were not included in this study, as they required steroids

Treatment

- Both topical and oral therapies are utilized by most for the treatment of BKC
 - Oral antibiotics are used when inflammation is significant and anti-inflammatory agents indicated
- Oral tetracycline derivatives, specifically doxycycline, are often used and effective in adults but should be avoided in children
 - Contraindicated in children without secondary dentition
 - Depresses bone growth
 - ??Consideration for kids 12+??
- In younger children, the macrolides may be used as a successful alternative

Treatment

- It is unclear if the mechanism of action is a direct effect on lipid synthesis or the influence on the microflora
- The dosage of erythromycin ranges in the literature from one-quarter full strength (50 mg/kg/day) to full-strength dosing
 - one-third to one-half of full-strength dosing divided into twice a day
 - generally well tolerated and effective, although some patients do develop gastrointestinal side-effects
- Zaidman et al advocates the use of azithromycin once daily in a dose of 15mg/kg/daily
 - better tolerated, more available, and convenient with the once-daily dosing

Treatment

- Topical steroids are often necessary to control corneal inflammation
- The lower potency steroids, such as loteprednol and fluorometholone, are often sufficient
- Typically taper quickly from more frequent dosing and less quickly once at infrequent dosing, tapering in some patients to once or twice a week with a weak steroid as necessary to control disease
- Higher potency steroids are necessary for brief periods.
 - Subtenon triamcinolone for patients with BKC who were intolerant or noncompliant with topical therapies
 - Dextensa may have a place???
- Very rarely, oral steroids may be necessary
- In extreme cases, systemic immunosuppression has been used, specifically azathioprine and methotrexate

Treatment

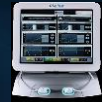- While necessary to control neovascularization and limit scarring, steroid therapy should be minimized, given the chronic nature of BKC and young age at presentation
- Topical cyclosporine A (CsA) is often used as a steroid-sparing agent
 - Doan et al. reported on the use of cyclosporine 2% in 11 patients with BKC. They initiated therapy with cyclosporine four times a day in addition to 1 week of topical dexamethasone.
- Inflammation did not recur during CsA monotherapy, during a mean follow-up of 12.8 months (range, 6–31 months). CsA therapy was stopped in eight patients (10 eyes) after a mean treatment duration of 13.9 months (range, 6–31 months), and no recurrences occurred during 10.3 months of follow-up (range, 6–12 months).

Treatment


- Local tolerance of CsA was good. The authors chose 2% cyclosporine over Restasis (Allergan, Irvine, CA, USA), which is 0.05%, because it was 40 times more concentrated than Restasis.
- Use of cyclosporine 0.2 and 0.5% have also been reported
 - topical Restasis has also been tried, given its readily available nature, in patients requiring long-term topical corticosteroids with some steroid-sparing effects
 - Newer / future of cyclosporine may have a role as well
 - OTX-101 - Cyclosporine 0.09% a novel nanomicellar formulation in a clear, preservative-free aqueous solution from SunPharma
 - CyclASol – Cyclosporine 0.05% in semifluorinated alkanes (SFAs) a preservative-free, well-tolerated non-stinging or burning vehicle from Novaliq

Treatment Considerations


- Thermal Pulsation
 - in-office treatment wherein plastic mushroom-shaped heaters are placed against the eyes. The eyelids are closed around the heaters, and a pair of air bladders is placed against the outside of the eyelids. The procedure lasts about twelve minutes per eye, during which time the mushrooms heat up the inside of the eyelids and the bladders squeeze from the outside. The intent is to heat the meibomian glands and express the meibum.
 - *Treatment of BKC is directed towards modification of meibomian gland disease and the bacterial flora of lid margin and conjunctiva, and control of ocular surface inflammation*



Treatment Considerations

- Micro Blepharo Exfoliation 
 - Device to scrape or exfoliate the eyelid margin. They are primarily intended to treat anterior blepharitis, but have also been promoted as helping to open up meibomian gland ducts. These devices are used only for in-office procedures,
 - The procedure lasts about 6 -8 minutes. Most patients simply report a tickling sensation. A numbing drop is usually placed in each eye prior to treatment for increased comfort.
 - *Treatment of BKC is directed towards modification of meibomian gland disease and the bacterial flora of lid margin and conjunctiva, and control of ocular surface inflammation*

Treatment Considerations

- Intense Pulsed Light 
 - Intense Pulsed Light (IPL). This procedure involves the use of intense pulsed light therapy around the eyelids. IPL is normally used to treat certain skin blemishes and small veins, but certain clinicians believe that treating the eyelids can improve dry eye symptoms.
 - The mechanism is still unknown, but thought to relate to the reduction of blood flow to the eyelid margin as a result of constriction of small veins, which in turn reduces inflammation and thereby improves certain symptoms of dry eye.
 - *Treatment of BKC is directed towards modification of meibomian gland disease and the bacterial flora of lid margin and conjunctiva, and control of ocular surface inflammation*

Conclusion

- BKC is a chronic disorder that is often overlooked by PCP's, OD's and OMD's until it is severe and threatens vision
- Correct diagnosis is often delayed for 2 years, and amblyopia may be present in 10–60%
- It should be suspected in children with chronic conjunctivitis and frequent chalazia
- Treatment is geared toward controlling inflammation and improving vision

Conclusion

- Start with proper eyelid hygiene, topical antibiotics, then oral antibiotics, and Omega-3 Supplements
- Topical steroids may be necessary, but their use should be minimized to control disease, and SE's monitored closely, then continued with steroid sparing agents (CsA)
- Newer treatments utilizing thermal pulsation, intense pulsed light or microblepharoexfoliation should be considered
- Increased awareness of this disorder is needed to allow for earlier treatment and/or referral

Thank you



Please feel free to contact me:

Nicholas Colatrella, OD, FAAO, Dipl AAO, ABO, ABCMO
NColatrella@pineconevisioncenter.com